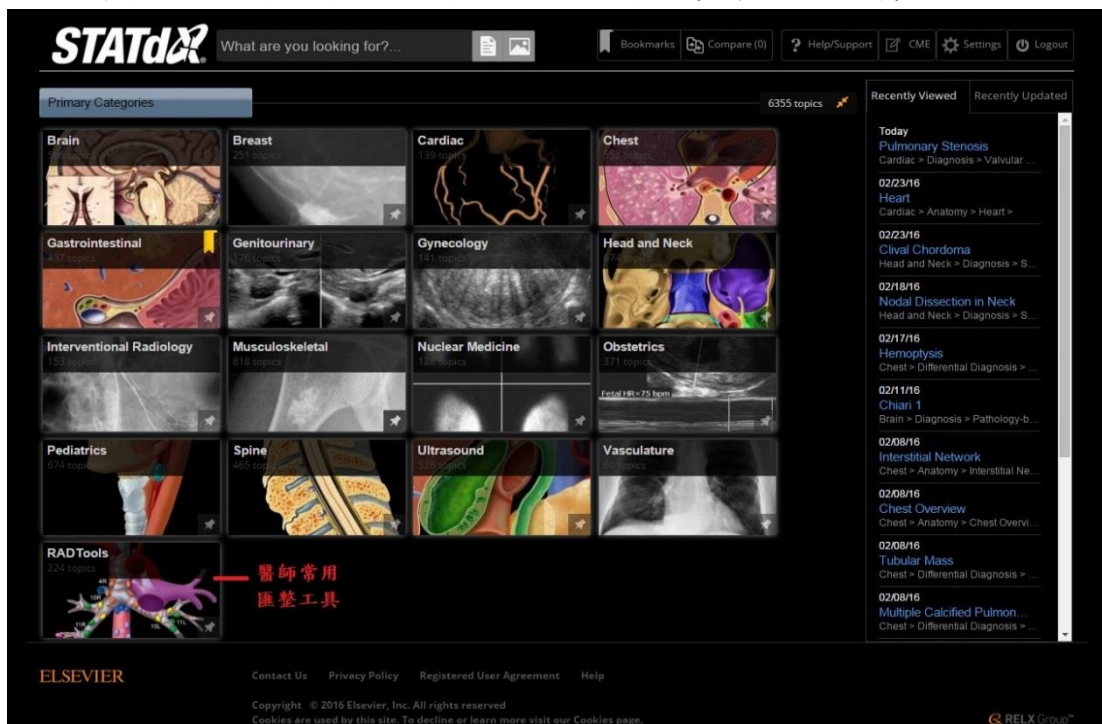


奇美醫院圖書館

STATdX 醫療影像系統介紹

圖書館 2016 年最新引進—STATdX 醫療影像系統資源（1 人版）。收錄內容來自 Amirsys 出版社所出版有關影像書籍。

電子資源可自院內/外電腦・筆電・智慧型裝置(手機・iPad 等)連線。



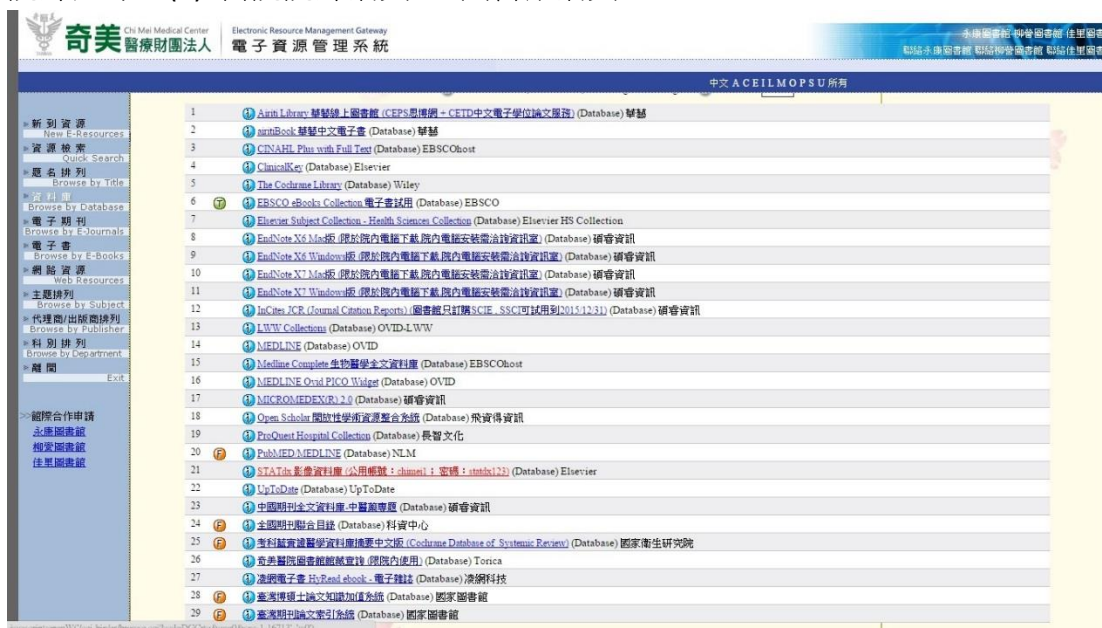電子資源管理系統 ERMG (<http://lib.chimei.org.tw/er/>) > 資料庫 > STATdX

院內連線：(1) 大聲公 > 電子資源 > ERMG

(2) 系統主程式 > Intranet > 電子資源入口 ERMG

(3) 大聲公“圖書館資訊欄”> 圖書館網頁 > ERMG

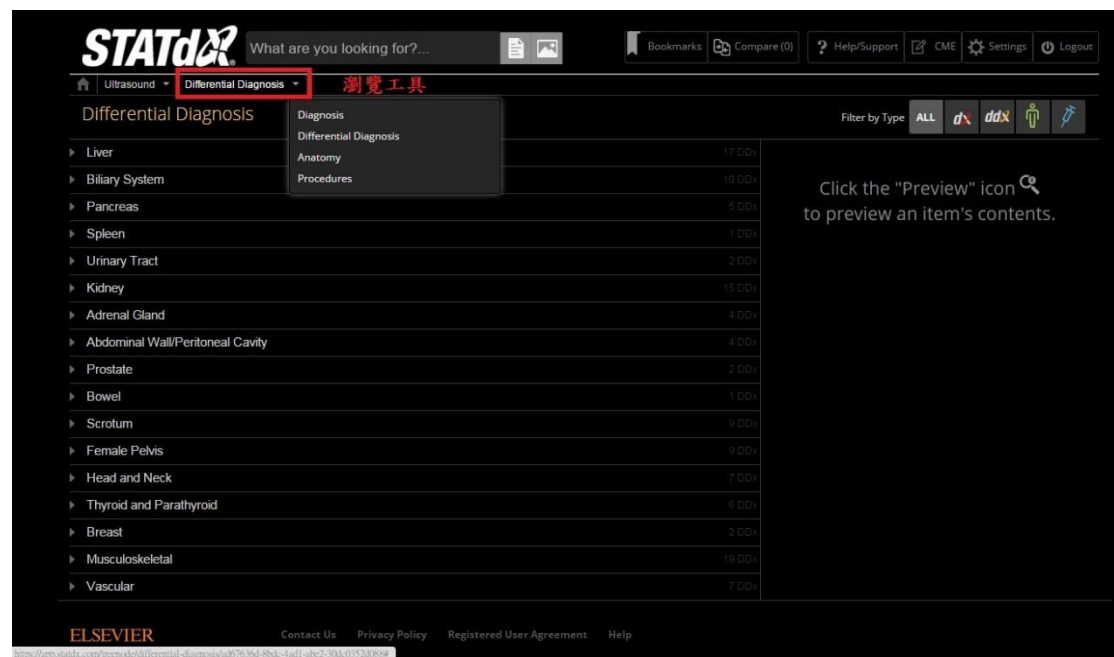
院外連線：(1) 醫院院外網頁 > 圖書館網頁 > ERMG



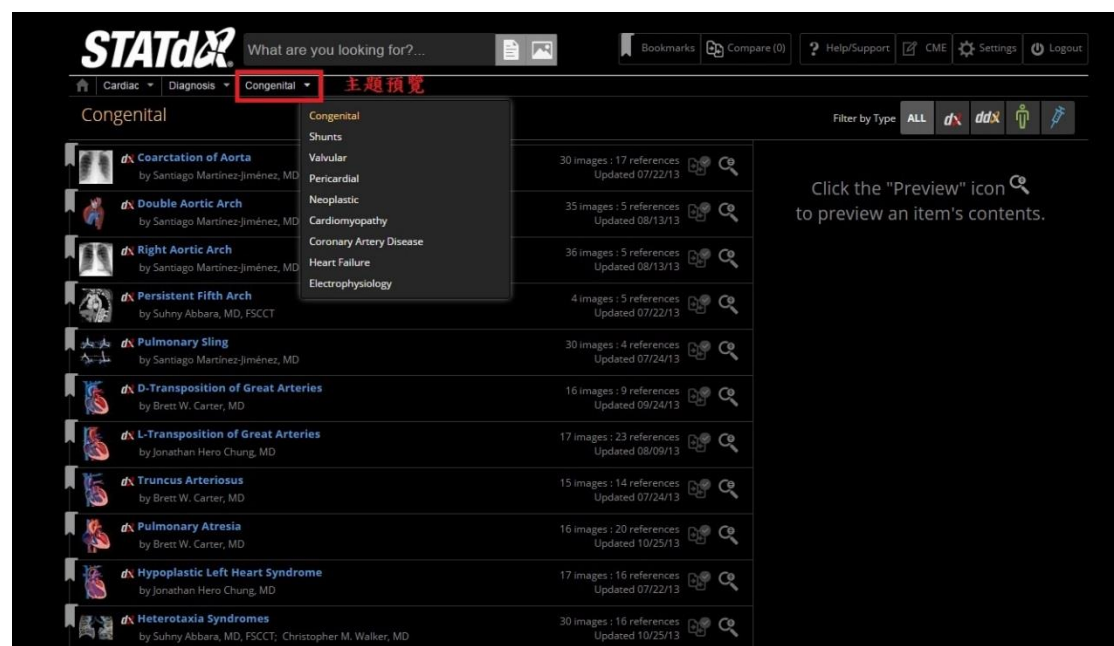
[STATdx 醫療影像系統說明](#)，如後附。

內容整合 Amirsys 出版社之 Diagnostic Imaging、Diagnostic Ultrasound、Specialty Imaging、Imaging Anatomy、EXPERTddx 等影像系列電子書，如附件[電子書清單](#)。

分層瀏覽相關主題



瀏覽相關診斷標題



STATdX What are you looking for? ... [Icons]

[Home] Cardiac ▾ Diagnosis ▾ Valvular ▾ **Pulmonary Stenosis ▾** 鉴别诊断清单

d Pulmonary Stenosis

Brett W. Carter, MD

KEY FACTS

Terminology

- Pulmonary stenosis (PS)
- Lesion resulting in obstruction of right ventricular outflow tract

Imaging

- Radiography: Enlargement of pulmonary trunk and main pulmonary artery
- CT
 - Poststenotic dilation of pulmonary trunk and left main bronchus
 - Thickened, immobile valve leaflets
 - Small valvular annulus
- Pericardial calcification involving aorta and pulmonary artery produce acquired PS
- MR: Determination of presence and extent of PS
 - Doming or windsock appearance of pulmonic valve
 - Narrowing of valve orifice

Top Differential Diagnoses

- Pulmonary artery hypertension
- Idiopathic dilatation of pulmonary trunk
- Proximal interruption of pulmonary artery

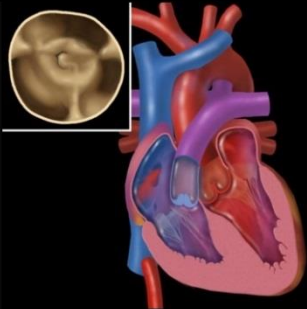
Pathology

- Majority of cases are congenital in etiology
- Acquired: Rheumatic heart disease, carcinoid syndrome, and infective endocarditis
- Severity of PS is determined by pressure gradient across pulmonic valve or pulmonary valve area

Clinical Issues

- Treatment
 - Trivial and mild PS: Observation and endocarditis prophylaxis prior to surgical

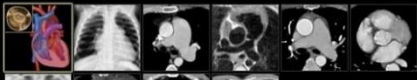
Aortic Stenosis
Transcatheter Aortic Valve Replace...
Aortic Regurgitation
Bicuspid Aortic Valve
Mitral Stenosis
Mitral Valve Prolapse
Mitral Regurgitation
Mitral Annular Calcification
Pulmonary Stenosis
Pulmonary Regurgitation
Tricuspid Stenosis
Tricuspid Regurgitation






Graphic shows morphologic features of pulmonary stenosis (PS) characterized by diffuse thickening of the pulmonic valve leaflets and fusion near the commissures, which results in narrowing of the valve orifice.







[Download to Presentation](#)

Selected Images 10














 Bookmarks
  Compare (0)
  Help/Support
  CME
  Settings
  Logout


Filter by Category

All

Search for Images Instead
 隨時比較

Small Bowel Carcinoma	Small Bowel Diverticula	Small Bowel Intussusception	Small Bowel NSAID Stricture	Small Bowel Obstruction
 Small Bowel Carcinoma Gastrointestinal by N. Small bowel (SB) ca edges, ± ulceration; N...				11 images : 7 references Updated 3/10/15 ar lesion: Short, well-demarcated ...
 Staging: Small Intestine Gastrointestinal by A. 50x less common th short segment of sma				43 images : 12 references Updated 10/8/10 ar, circumferential narrowing: Involves
 Duodenal Carcinoma Gastrointestinal by Michael P. Federle, MD, FACR ... Thin-section CECT with water for luminal ... Duodenal ulcer: Spasm may narrow lumen. Zollinger ... evaluation and staging of small intestine neoplasms. ...				39 images : 18 references Updated 3/9/15
 Intestinal Metastases and Lymphoma Gastrointestinal by Michael P. Federle, MD, FACR ... Vasculitis (Small Intestine), ... avium-intracellulare (MAI): Thickened SB folds, fine nodularity; ... CMV: Thickened folds, spiculation, ulcers, narrow lumen; ...				39 images : 15 references Updated 4/10/15
 Colon Carcinoma Gastrointestinal by Michael P. Federle, MD, FACR ... protruding lesion with little elevation of ... Cancer: Short segment involvement ± nodal enlargement. ... micro- to normocytic anemia; Carcinoembryonic ...				48 images : 14 references Updated 3/18/15
 Familial Polyposis and Gardner Syndrome Gastrointestinal by Michael P. Federle, MD, FACR ... Usually more prominent in right colon and distal small bowel. Barium studies: Innumerable small or tiny radiolucent nodules. Distinguished by ...				46 images : 14 references Updated 3/19/15
 Segmental Colonic Narrowing Gastrointestinal by Michael P. Federle, MD, FACR Updated 10/21/08				15 images Updated 10/21/08

Click the "Preview" icon  to preview an item's contents.